

## Case Report

# Broad Ligament Fibroid - An Unusual Presentation

Hrishikesh Mandhane\* and Aher G.S

Department of OBGY, PDVVPF'S Medical College, India

### \*Corresponding Author

Dr. Hrishikesh Mandhane  
Department of OBGY,  
PDVVPF'S Medical College, India  
E-mail: [hrishmmandhane@gmail.com](mailto:hrishmmandhane@gmail.com)

### Abstract

Giant fibroids are known to arise from the uterus, but occasionally from the broad ligament also. This is a case report of a giant broad ligament fibroid, reported for its rarity, and the diagnostic difficulties.

### Keywords:

Fibroid,  
Broad ligament fibroid

## 1. Introduction

Extra-uterine fibroids though do occur, but are not common as uterine fibroids. Among the extra-uterine Fibroids, broad ligament fibroids are the most common to occur [1] although it's overall incidence being rare. Because of its rarity it poses specific diagnostic difficulties causing an error in making the final diagnosis and therefore the management. This is one such case report where a diagnosis of malignant ovarian tumour was made and the histopathology confirmed the diagnosis of broad ligament fibroid.

## 2. Case Report

Forty-eight years old para 3, living 3, came to the Emergency Department of Christian Medical College & Hospital with the history of abdominal distension for one year that rapidly increased over the past 1 to 2 months. Along with this she had difficulty in passing urine. There was history of indigestion. No history of weight loss/ anorexia/ fever. Her menstrual cycle was normal. Examination: A42year lady of average build and nutrition. No pallor. BP 120/70 mm Hg, Pulse 90 per minute, RR 12 per minute. No significant lymphadenopathy. Systemic examination was normal. Abdomen was distended. A firm, smooth surfaced, regular, non-tender mass of approximately 32 weeks size was felt arising out of the pelvis. No shifting dullness was present. Speculum examination revealed normal cervix and vagina. Per vaginum examination cervix was firm, regular but deviated to the left side; uterus was normal-sized, anteverted, mobile and non-tender; a firm to hard, non-tender mass was felt in the pouch of Douglas extending into the abdomen almost reaching up to 32 weeks size. Per rectal examination was normal.

### 2.1 Investigations

Hemoglobin 11.6 gm%, Blood Urea 24 mg/dl, Serum Creatinine 0.8 mg/dl, Random blood sugar 100 mg/dl, Na - 140 K - 4 Cl - 100 T co2 - 25, Urine c/s- no growth. Ultrasonography of the abdomen -huge complex mass arising from the pelvis and extending into the abdomen occupying almost whole of the abdomen; echo texture complex predominantly echogenic with multiple poorly hypochoic areas and some large echopoor areas; margins of the mass well-defined. No free fluid.

**2.2 Impression:** Probably malignant ovarian tumour.

### 2.3 Management

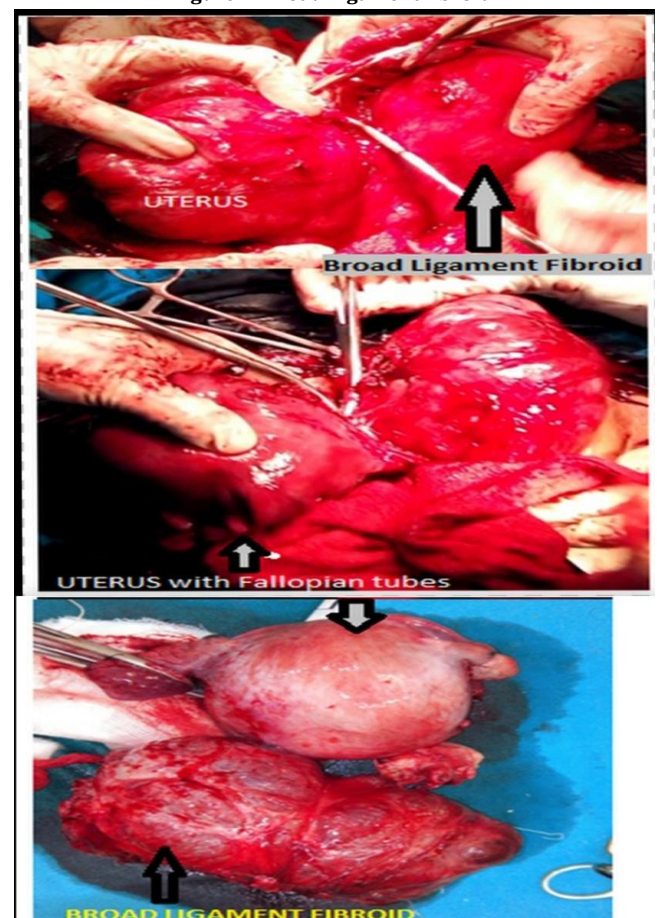
With a probable diagnosis of malignant ovarian tumour the patient was taken up for an exploratory laparotomy.

### 2.4 Operative findings

Minimal bloodstained ascitic fluid was drained. Uterus was normal sized & serosa appeared normal. Right sided parovarian tumour 25 cms 25 cms (figure 1) with solid and cystic areas, external capsule intact, no papillae seen on the external surface. Left ovary was enlarged

to 5 cms x 5 cms and had solid & cystic areas. A subserous calcified fibroid 6 cms x 5 cms was seen on the posterior surface of the uterus close to the fundus. Omentum was grossly normal. Rests of the abdominal organs were normal. Total abdominal hysterectomy & bilateral salpingo-oophorectomy done. Sutures were removed on the 10th postoperative day. Patient was discharged in a satisfactory condition.

Figure 1: Broad Ligament fibroid



### 2.5 Pathology

#### Gross:

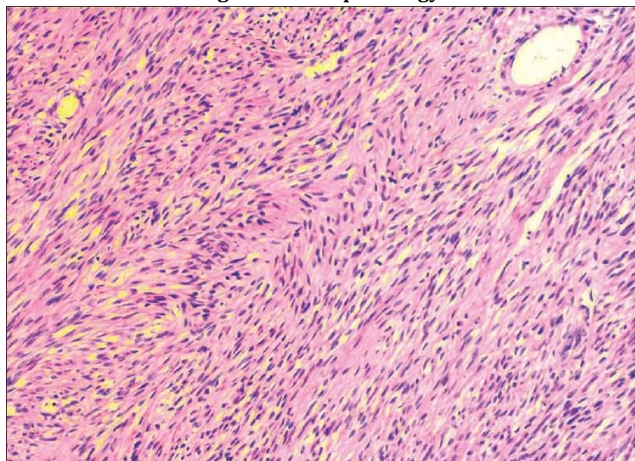
Mass 25 cms x 25 cms and weighing 1800 gms, External surface smooth. Cut section shows predominantly solid areas along with cystic areas containing yellowish gelatinous substance and altered

hemorrhagic fluid. Right ovary adherent to the posterior surface of the mass. Left ovary enlarged but looked normal. Uterus 12cms x 10cms x 8cms, Cervix normal. Left superior aspect of the uterus shows a subserosal fibroid 6 cms x 5 cms. External surface of the fibroid shows dilated prominent blood vessels.

**Microscopic:**

Mass showed benign spindle cell tumour of the stroma tissue origin Suggestive of Leiomyoma. (Figure 2).

**Figure 1: Histopathology**



**3. Discussion**

Uterine leiomyomas, also known as myomas or fibroids, are by far the commonest benign uterine tumours. They are usually diagnosed on physical examination. They are most commonly intramural, subserosal, submucosal and cervical. Myomas and fibromyomas are not uncommon in the round, ovarian and broad ligaments [2], they are found in association with similar uterine tumours and their pathology and complications are the same as fibroids. Fibroids in the broad ligament though not so common, but are

well known for achieving enormous size; which may mimic a malignancy of the pelvis thereby altering the course of treatment offered. This case reports one such incidence where the patient presented with a mass per abdomen that seem to be arising out of the pelvis, had features of malignancy both clinically as well as radiologically and received treatment for the same while histopathology confirmed it as a benign broad ligament fibroid. Had it been diagnosed initially the major debulking surgery could be limited to a simple hysterectomy. Asimilar case report has also been reported by Gowri et al[3] for its rarity , and the diagnostic difficulties it posed. Degenerative changes in the leiomyomas are considered to be due to inadequate blood supply and degenerative changes seem to depend on the degree and rapidity of the onset of vascular insufficient changes are the commonest form of degeneration. The fibroid in our report had undergone calcific degeneration. Bose et al have also reported a similar case of calcified broad ligament fibroid [4]. There is no particular relationship between any symptom or group of symptoms and the incidence of degenerative changes.

**4. Conclusion**

The broad ligament benign tumour even though being uncommon can grow to a large size as exemplified in this case. Degenerative changes occur even in such extra-uterine fibroids.

**References**

- [1] Bhatla N. Tumours of the corpus uteri. In: Jeffcoats Principles of Gynaecology 6th edn. Arnold Printers, London; 2001: pp 470.
- [2] Jonathan S Berek. Benign Diseases of the Female Reproductive Tract. In: Novak's Gynecology 13<sup>th</sup> edn. Lippincott Williams & Wilkins, Philadelphia; 2002: pp 380.
- [3] Gowri V, Sudheendra R, Oumachigui A, Sankaran V. Giant broad ligament leiomyoma. *Int J Gynaecol Obstet* 1992; 37(3): 207-10.
- [4] Bose GK, Saha SK, Adhikari S, Chatterjee S. An unusual case of calcified broad ligament fibroid. *J Obstet Gynecol Ind* 1996; 46(3): 435-36.