

Original Article

Prenatal development of *yankasa sheep (Ovis aries)* kidney: A histomorphometric study

A. Bello^{*1}; D. I Dabai¹; M.A Umaru², S.A. Shehu¹; M.I. Jimoh¹

¹Department of Veterinary Anatomy, Faculty of Veterinary Medicine, Usmanu Danfodiyo, University Sokoto, Nigeria

²Department of Theriogenology and Animal production, Usmanu Danfodiyo University, Sokoto, Nigeria.

*Corresponding Author

Dr. Abdulrahman Bello

Department of Veterinary Anatomy,
Faculty of Veterinary Medicine,
Usmanu Danfodiyo, University Sokoto, Nigeria
E-mail: abccrcfge28@gmail.com

Keywords:

Histomorphometry,
Kidney,
Prenatal development,
Yankasa sheep

Abstract

A Histomorphometric study was conducted on the kidney of seventeen (17) fetuses of the *Yankasa sheep (Ovis aries)* collected from the Sokoto metropolitan abattoir, over a period of one month at different gestational ages. The approximate age of the fetuses was estimated from the crown vertebral rump length (CVRL) and samples were categorised into first, second and third trimester. Out of the seventeen (17) fetuses at different gestational age used for the study, 7 (48%) were females while 10 (52%) were males. 6(35%) fetuses belong to first trimester, 5(30%) belong to second trimester and 6(35%) belong to third trimesters of pregnancy respectively. The mean crown vertebrate-rump length (CVRL) ranged from 12.47 ± 1.80 cm at first trimester to 33.79 ± 1.52 cm at third trimester. Histological observation shows that the kidney appeared to have two zones via cortex and medulla right from first to third trimester. The development of renal tissues were found to be in succession, from the stage of mesenchyme cells, developing glomerulus and finally to fully developed glomerulus with advancement of gestational age among the three groups. The duct system also followed the same trend of development from immature to matured duct system. The cortex of the first trimester kidney was found to have numerous mesenchymal cells and connective tissues with few developing glomerulus. At second trimester few fully developed glomerulus were found, moderate number of mesenchyme cells and immature developing duct system. Numerous developed glomerulus and matured duct system with moderate developing glomerulus and connective tissue were seen at third trimester. The medulla at first trimester shows only various types of connective tissue (collagen, reticular and elastic) fibers and mesenchyme cells. At second trimester the medulla was found to have numerous developing collecting ducts, few developed collecting ducts and few mesenchyme cells. Developed collecting ducts were predominant in the medulla at third trimester with few mesenchyme cells. The histological differentiation of the *Yankasa sheep* kidney is similar to that of ovine, bovine, equine, Llama, and guanaco but differs from that of the feline, canine and porcine. Mean while, considering the histological features observed in the study, the *Yankasa sheep* kidney may become fully matured and functional at post-natal age.

1. Introduction

Yankasa sheeps are member of a class of animals called ruminants. These animals ruminant (chew their cud). Unlike other animals, they have four-compartment stomachs especially designed to digest roughage (food high in fiber) such as grass, hay and silage [1]. Anatomically, the ruminant stomach comprises of the rumen, the honey-combed reticulum, the leaf like Omasum and the abomasum or true stomach [2]. The size relationship of four chambers changes as the animal grows up. [1] Small ruminants, (sheep and goats) are increasingly becoming a major source of animal protein in Nigeria, contributing over 30 percent to total meat consumption in the country. [3]

Yankasa sheeps are widely distributed throughout the world. The total world cattle population is estimated to be more than 1.4 billion head, with about 35 percent in Africa, 23 percent in Asia, 17 percent in South America, 12 percent in North and Central America, 10 percent in Europe, and 3 percent in Oceania [4].

Histomorphological studies of prenatal development of various organs in *yankasa sheeps* spp has been carried out extensively [1][5][6]-[11] but little of such studies have been conducted on the developmental changes of the *yankasa sheeps* fetal kidney in this area. However, there is thus, paucity of information on the prenatal development of *yankasa sheeps* kidney [12]; hence the present study was undertaken to bridge the gap of the existing information.

2. Materials and method

The study was carried out on 17 fetuses of the *yankasa sheeps* collected from the metropolitan abattoir, Sokoto, Nigeria, at different gestational ages. The collected fetuses were then taken to the Veterinary Anatomy laboratory of Usmanu Danfodiyo University, where the weight and age of the fetus were determined. The fetal body weight was measured using electrical (digital) weighing balance for the smaller fetuses and compression spring balance (AT-1422), size C-1, sensitivity of 20kg X 50g in Kilogram for the bigger fetuses.

The approximate age of the fetuses was estimated using the following formula as adopted by Gall. *et al*, 1994.[13]

$$G.A = (CVRL + 30.15) / 2.74 \quad \dots\dots\dots \text{Where GA is in days}$$

Where GA(Gestational Age) is in days, CVRL(Crown Vertebral rump Length) is in centimeter, and measured as a curved line along the vertebral column from the point of the anterior frontal bone following the vertebral curvature to the base of the tail [2]. Based on this, the following guide fetues were place in to various stages of gestational ages (trimester):

First Trimester = 1-51 days; Second Trimester = 52-102 days; Third trimester = 103-153days

The kidneys of each fetus were collected by placing the fetus on dorsal recumbency and a mid-ventral skin incision was made via the abdomino-pelvic region down to the thoracic region. The

abdomino-thoracic content was removed entirely to gain access to the position of the kidneys.

1cm² thick of sample from each group was collected and fixed in 10% formalin solution. After fixation was achieved, the tissue sample was processed for paraffin blocks preparation. The sections of 5µm were subjected to haematoxylin and eosin for routine morphology [14]. The standard sections were examined under light microscope and micrographs taken using digitalized Sony camera with 12.1 mega pixel.

3. Result and Discussion

Out of the twenty five (17) fetuses at different gestational age used for the study, seven (48%) were females while ten (52%) were males. 6(35%) fetuses belong to first trimester, 5(30%) belong to second trimester and 6(35%) belong to third trimesters of pregnancy respectively. The mean crown vertebrate-rump length (CVRL) ranged from 12.47 ± 1.80 cm at first trimester to 33.79 ± 1.52 cm at third trimester as shown in table 1.

From the study, the result shows that with the advancement of gestation the morphometric data were increasing progressively across the various stages of development as shown in table 2. This is in accordance with the finding of Hena *et al.*, 2012, on pigeon, Bello *et al.*, 2013 on cattle kidney and Bello *et al.*, 2012 on camel digestive tract.[2][3][15]

Table 1: The Mean CRVL, Mean Weight and Sex of the yankasa sheeps foetuses at various trimesters of age

Trimester	Mean CRVL (cm±SEM)	Sex		Mean Weight (g±SEM)
		Male	female	
1 st	12.47±1.80	4	2	126.15±4.74
2 nd	22.16±1.17	2	3	452.12±4.25
3 rd	33.79±1.52	4	2	1801.39±7.58
Total =		10	7	

Table 2: The Mean ±SEM of biometrical parameters of right and left yankasa sheeps kidneys in relation to stages of development

Parameters	1 st Trimester	2 nd Trimester	3 rd Trimester
Sample size	6	5	6
Mean Weight (g±SEM)			
Right Kidney	0.68±0.19	2.00±0.17	3.74±0.28
Left kidney	0.68±0.19	2.44±0.28	3.88±0.30
Mean Length(cm±SEM)			
Right kidney	1.27±0.19	2.36±0.11	2.86±0.04
Left kidney	1.44±0.13	2.48±0.05	3.88±0.30
Mean Width (cm±SEM)			
Right kidney	0.82±0.11	1.44±0.10	1.66±0.08
Left kidney	0.83±0.12	1.48±0.08	1.68±0.08
MeanVolume(cm ³ ±SEM)			
Right kidney	0.82±0.29	2.02±0.17	3.18±0.31
Left kidney	0.82±0.29	2.50±0.21	3.20±0.36

Histological observation shows that the kidney appeared to have two zones via cortex and medulla right from 1st trimester as shown in figures 1-4. The development of renal tissues were found to be in succession, from the stage of mesenchyme cells, developing glomerulus and finally to fully developed glomerulus with advancement of gestational age among the three groups as shown in figures 1-8. The duct system also followed the same trend of development from immature to matured duct system.

The cortex of the first trimester kidney was found to have numerous mesenchymal cells and connective tissues with few developing glomerulus (Fig 1). At second trimester few fully developed glomerulus were found, moderate number of mesenchyme cells and immature developing duct system (Fig 2). Numerous

developed glomerulus and matured duct system with moderate developing glomerulus and connective tissue were seen at third trimester (Fig. 3). This is in agreement with Onarlioglu *et al.*, (1997)[17] that observed no developed glomeruli in the kidneys where dense mesenchymal tissue take place in early stage of development in rat foetus. The population of mesenchyme cells reduced in the second trimester, together with few fully developed glomerulus and immature developing duct system (Fig. 2). There was slight coiling of the duct system at the cortex of the kidney (Fig 2 and 3). This is in line with that observed by El-Salmi and Amri (2012) on Sudanese sheep [16].

The glomerulus in the cortex of the first trimester kidney was found to have undifferentiated juxtaglomerula complex cells and connective tissues with few developing glomerulus (Fig 5). At second trimester few fully developed glomerulus were found with differentiated juxtaglomerula complex cells and moderate number of mesenchyme cells and immature developing duct system (Fig 6). Numerous developed glomerulus and matured duct system with moderate developing glomerulus and connective tissue were seen at third trimester with clear differentiated juxtaglomerula complex cells (Fig. 7 and 8). This is in agreement with Onarlioglu *et al.*, (1997)[17] that observed no developed juxtaglomerula complex cells in the glomeruli in the kidneys where dense mesenchymal tissue take place in early stage of development in rat foetus. The appearance and differentiation of the juxtaglomerula complex cells and the population of mesenchyme cells reduced in the second trimester, together with few fully developed glomerulus and immature developing duct system (Fig. 6 and 7). This is in line with that observed by El-Salmi and Amri (2012)[16] on Sudanese sheep and Franco *et al.*, (2004) on Llama.

The medulla at first trimester shows only various types of connective tissue (collagen, reticular and elastic) fibers and mesenchyme cells (Fig 9). At second trimester the medulla was found to have numerous developing collecting ducts, few developed collecting ducts and few mesenchyme cells (Fig 10). Developed collecting ducts were predominant in the medulla at third trimester with few mesenchyme cells (Fig 11). This is also in line with that observed by Franco *et al.*, (2004)[18] on Llama and El-Salmi and Amri (2012) on Sudanese sheep. At third trimester the kidneys showed predominant developed collecting ducts and few mesenchyme cells, which showed the kidneys, were still developing. This trend of growth was in accordance with the findings of Bello *et al.*, (2012),[2] who reported that variable growth and structural diversities at different stages of development of an organ is a normal phenomenon for accommodating and molding of the organ.

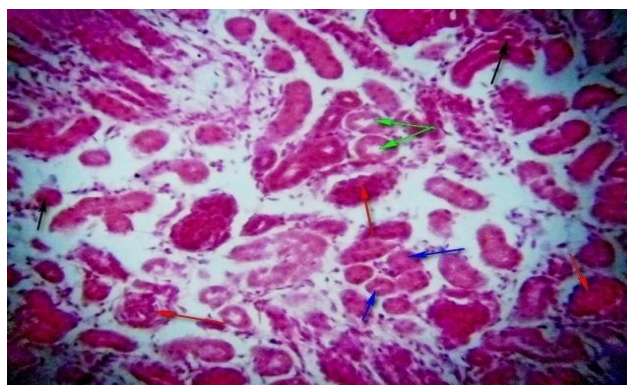


Fig. 1: Photomicrograph of Yankasa sheep kidney (cortex) at 1st Trimester showing premature glomerulus (Red arrow) with developing blood vessels (Black arrow) and prominent mesenchyme cells H&E x200.

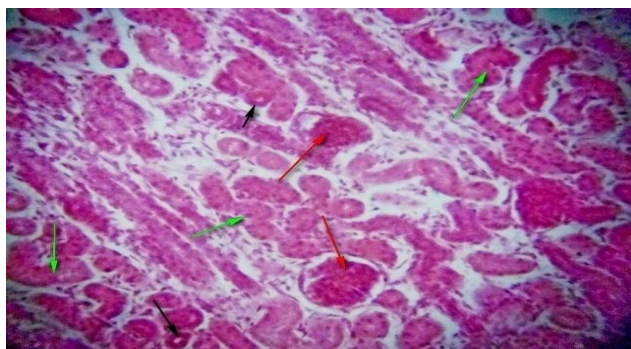


Fig. 2: Photomicrograph of Yankasa sheep kidney (cortex) at 2nd Trimester showing premature and mature glomerulus (Red arrow), differentiated connective tissues (Red arrow) with prominent blood vessels (Black arrow) and proliferative collecting ducts H&E x200.

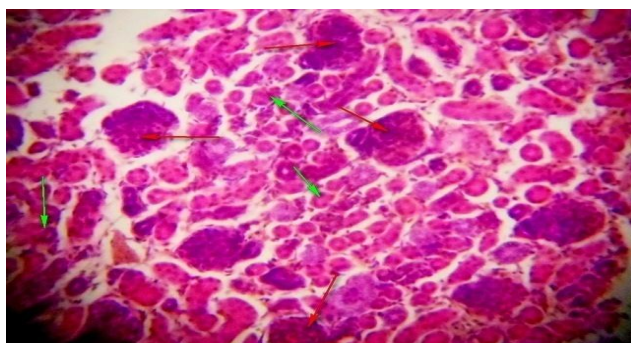


Fig. 3: Photomicrograph of Yankasa sheep kidney (cortex) at 3rd Trimester showing mature glomerulus (Red arrow), differentiated connective tissues with numerous blood vessels (Green arrow) and mesenchyme cells H&E x200.

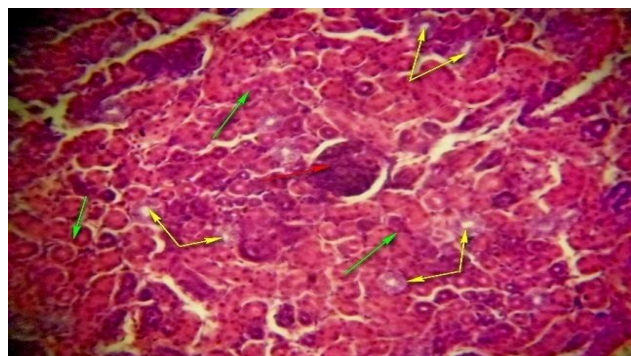


Fig. 4: Photomicrograph of Yankasa sheep kidney (cortex) at 3rd Trimester showing mature glomerulus (Red arrow), with well-developed connective tissues and blood vessels (Yellow arrow) and mesenchyme cells H&E x200

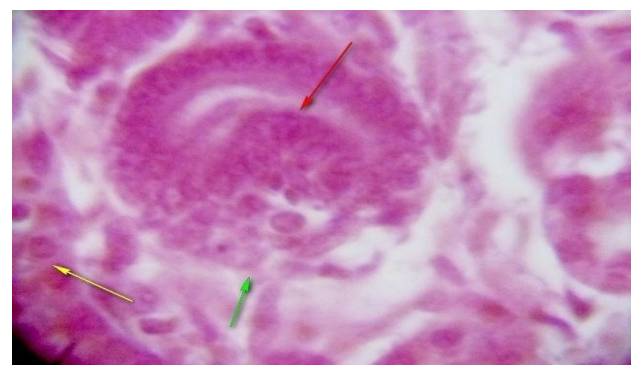


Fig. 5: Photomicrograph of Yankasa sheep kidney (cortex) at 1st Trimester showing premature glomerulus (Red arrow) undifferentiated juxtaglomerula complex (Green arrow) and mesenchyme cells (yellow arrow) H&E x400.

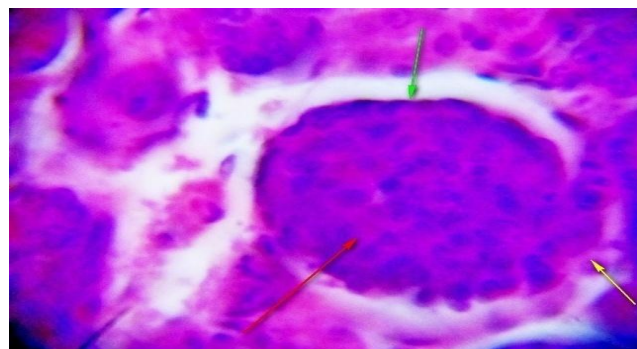


Fig. 6: Photomicrograph of Yankasa sheep kidney (cortex) at 2nd Trimester showing mature glomerulus (Red arrow), with differentiated epithelium of the bowman's capsule (Green arrow), differentiated developing juxta glomerula complex (yellow arrow) and mesenchyme cells H&E x400.

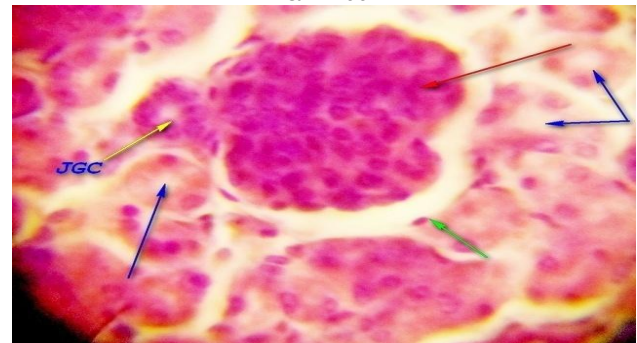


Fig. 7: Photomicrograph of Yankasa sheep kidney (cortex) at 3rd Trimester showing mature glomerulus (Red arrow), with differentiated epithelium of the bowman's capsule (Green arrow), differentiated developing juxta glomerula complex (yellow arrow) and mesenchyme cells H&E x400.

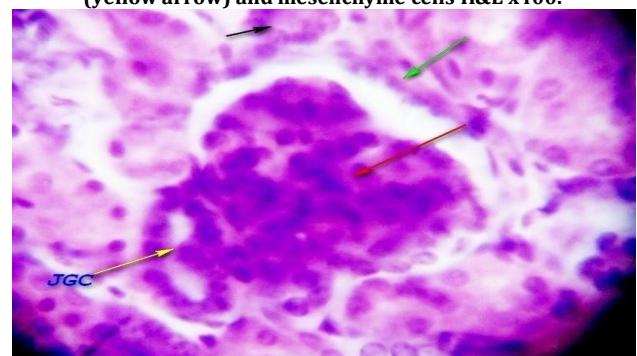


Fig. 8: Photomicrograph of Yankasa sheep kidney (cortex) at 3rd Trimester showing mature glomerulus (Red arrow), with differentiated epithelium of the bowman's capsule (Green arrow), differentiated developed juxta glomerula complex (yellow arrow) and mesenchyme cells H&E x400.

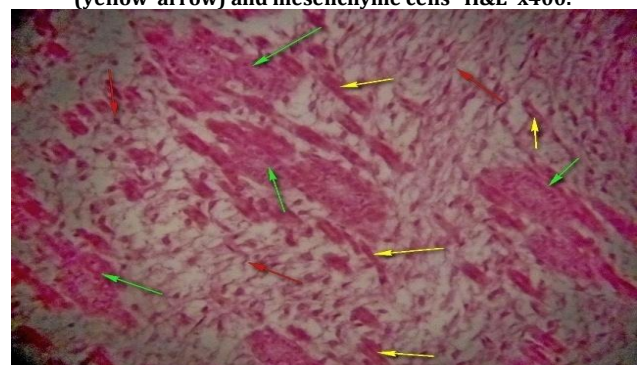


Fig. 9: Photomicrograph of Yankasa sheep kidney (medulla) at 1st Trimester showing premature connective tissues; collagen (green arrow), reticular (Red arrow), elastic (Yellow arrow) and mesenchyme cells (yellow arrows) with no evidence of blood vessels H&E x200.

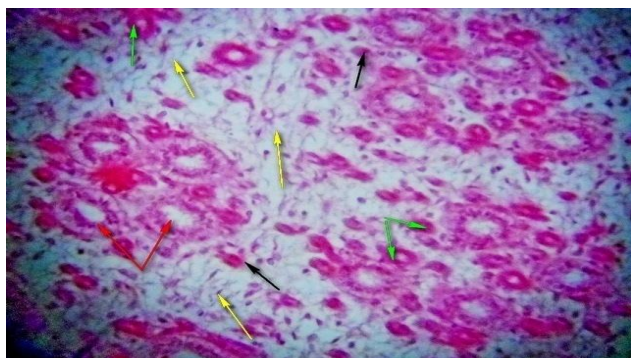


Fig. 10: Photomicrograph of Yankasa sheep kidney (medulla) at 2nd Trimester showing premature connective tissues; collagen with evidence of blood vessels (green arrow), reticular (Yellow arrow), elastic (Black arrow) developing collecting ducts (Cd), developed collecting ducts (C) and mesenchyme cells H&E x200.

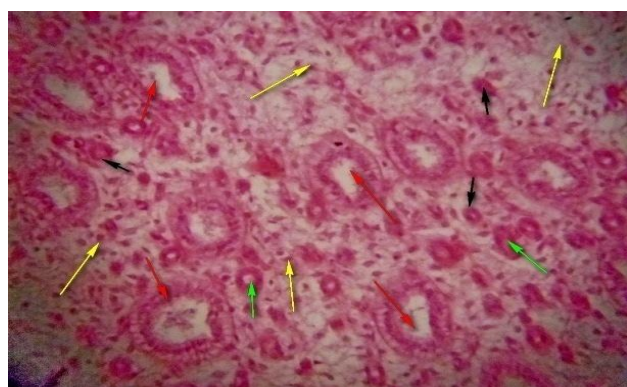

Fig.11: Photomicrograph of Yankasa sheep kidney (medulla) at 3rd Trimester showing matured connective tissues; collagen with numerous blood vessels (green arrow), reticular (Yellow arrow), elastic (Black arrow) developed collecting ducts (C) and mesenchyme cells H&E x200.

4. Conclusion

In conclusion, the histological differentiation of the *Yankasa sheep* kidney is similar to that of Ovine, Bovine, Equine, Llama, and Guanaco but differs from that of the feline, canine and porcine. Mean while, considering the histological features observed in the study, the Bovine kidney may become fully matured and functional at post-natal age.

References

- [1] Asari M., Oshige H., Wakui S., Fukaya K., Kano Y. Histological development of bovine abomasus. *Anat. Anz.* 1985; 159: 1-11.
- [2] Bello A., Onyeonusi B.I., Sonfada M.L; Adeyanju J.B., Umaru M.A. A biometric study of the digestive tract of one-humped camel (*Camelus dromedarius*) fetuses, *Scientific Journal of Zoology* 2012; 1(1): 11-16.
- [3] Bello A., Sonfada M.L., Umar A.A., Umaru M.A., Shehu S.A., Hena S.A., Onu J. E., Fatima O.O. Age estimation of camel in Nigeria using rostral dentition: *Scientific Journal of Animal Science* 2013; 2(1): 9-14.
- [4] Abd-Elmaksoud, A. Morphological, glycohistochemical and immunohistochemical studies on the embryonic and adult bovine testis. Ph.D. Thesis, Ludwig-Maximilians-Universitat 2005.
- [5] Wilson R. T.; Araya, A. and Melaku, A. The One-Humped Camel: An Analytical and Annotated Bibliography 1980-1989. UNSO Technical Publication. Bartridge Partners, Umberleigh, North Devon EX379AS U.K 1990.
- [6] Reece, W. O. Physiology of domestic animals. Williams and Wilkins. CH. 11, 1997: pp. 334.
- [7] Bustinza, A.V. South American Camelids. In: IFS Symposium Camels. Sudan. 1979: Pp 73-108.
- [8] Franco A, Masot A.J, Gómez L, Redondo E. Morphometric and immuno histochemical study of the rumen of red deer during prenatal development. *Journal of Anatomy*; 2004; 204: 501-513.
- [9] Belknap, E. B. Medical problems of llamas. In: The Vet. Cl. of North American food and Animal Practice, Update on Llama Medicine. Johnson, L. W. (Editor). Philadelphia, W. B. Saunders Co. 1994
- [10] Watrous, B.J.; Pearson, E.G.; Smith, B.B.; Snyder, S.P.; Blythe, L.L.; Riebold, T.W. & Hedstrom, O.R. Megaesophagus in 15 llamas: a retrospective study (1985-1993). *J. Vet. Intern. Med.*, 1995; 9:92-9.
- [11] Jamdar, M. N. & Ema, A. N. The submucosal glands and the orientation of the muscul-ature in the oesophagus of the camel. *J. Anat.*, 1982; 135:165-71.
- [12] Luciano, L., Voss-wermbter, G., Behnke, M., Engelhardt, W. V. and Reale, E. Die Struktur der Magenschleimhaut beim Lama (*Lama guanacoe* and *Lama llama*) I. Vormägen. *Gegenbauers Morphol. Jahrb.* 1979; 125: 519-549.
- [13] Gall, C.F; Stier, CH and Frahm, K. Age estimation of *yankasa sheep* fetus. *Small Ruminant Res.*, 1994; 14: 91-94.
- [14] Luiz C. J. and Jose C. Basic Histology Text and Atlas 11th ed. McGraw-Hill 2005.
- [15] Hena S. A, Sonfada M.L., Onyeonusi B.I., Kene R.O.C, Bello A. Radiographic studies of developing calvaria at prenatal stages in one-humped camel. *Sokoto Journal of Veterinary Sciences.* 2012; 10(1): Pp13-16. <http://dx.doi.org/10.4314/sokjvs.v10i1.3>
- [16] El-Salmi and Amri. Genetic Diversity and relationships of Indigenous Saudi Arabia Camel (*Camelus dromedarius*) Populations. In: The proceedings of the Proceedings of the 3rd Conference of the International Society of Camelid Research and Development, 2012: Pp 40
- [17] Onarlioglu, B., GURSOY E., and KALOGLU, C. Renal Morphogenesis of rat fetus. *Turk. J. Anim. Sci.* 1997; 21: 493-496
- [18] Franco A, Masot A.J, Gómez L, Redondo E. Morphometric and immuno histochemical study of the rumen of red deer during prenatal development. *Journal of Anatomy*; 2004; 204:501-513.